



# Use of the 308-nm excimer laser for psoriasis and vitiligo

Thierry Passeron, MD\*, Jean-Paul Ortonne, MD

Department of Dermatology, Archet 2 Hospital, 06202 NICE Cedex 3, France

**Abstract** The 308-nm excimer laser represents the latest advance in the concept of *selective phototherapy*. It emits a wavelength in the UV-B spectrum and thus shares the same indications as conventional phototherapy. Like other laser devices, the 308-nm excimer laser emits a monochromatic and coherent beam of light, can selectively treat a lesion while sparing surrounding healthy skin, and can deliver high fluencies. Clinicians have taken advantage of these properties to treat dermatologic disorders since 1997, with psoriasis and vitiligo attracting most attention. Initially, high fluencies (minimal erythemal dose, 8-16) were used, with excellent clinical results, to treat psoriasis vulgaris. The significance of side effects and the potential long-term carcinogenic risk associated with such fluencies have resulted in medium doses (about 3 minimal erythemal dose) being recommended, however. Interestingly, taking advantage of the selectivity of the laser, newer treatment protocols adapt the dose to the lesion and not to the minimal erythemal dose, as is the case for conventional phototherapies.

Many prospective study series have also shown the efficacy and the good tolerance of the 308-nm excimer laser in the treatment of localized vitiligo. Induced rates of repigmentation seem to be higher than with narrowband UV-B. Moreover, the selectivity of the treatment prevents irradiation of healthy skin and limits unsightly tanning of surrounding skin. Aesthetically pleasing results are usually not achieved in extremities and bony prominences, which are not good indications for this technique. Combining the 308-nm excimer laser with 0.1% tacrolimus ointment has provided very interesting results, which need to be confirmed in larger series. The absence of actual data concerning the long-term risk for skin cancer after this treatment means that it should be considered with caution. Combination with topical steroids appears to be synergistic and potentially reduces long-term side effects; again, prospective data are lacking.

© 2006 Elsevier Inc. All rights reserved.

## Introduction

Thanks to its efficacy and good tolerance, phototherapy is now considered to be a gold standard therapy for many dermatoses, and treatments with UV types A and B are

commonly used in dermatology. Unlike UV-A therapy, UV-B therapy does not require photoreactive molecules for efficacy. Monochromatic studies showed that the best spectrum of wavelength for treating psoriasis is 300 to 313 nm, which led to the development of narrowband UV-B (NB-UVB).<sup>1</sup> The excimer laser represents the latest advance in this concept of *selective phototherapy*. It emits a wavelength of 308 nm and shares the physical properties of lasers: a monochromatic and coherent beam of light, selective treatment of the target, and the ability to deliver

\* Corresponding author. Tel.: +33 4 92 03 62 23; fax: +33 4 92 03 65 58.

E-mail address: passeron@unice.fr (T. Passeron).

high fluencies. The 308-nm excimer laser was first used in dermatology in 1997 for treating psoriasis.<sup>2</sup> Since then, many studies have evaluated this new device in a number of dermatologic disorders. Psoriasis and vitiligo have each been further investigated, and the use of excimer lasers for both conditions is now approved by the US Food and Drug Administration. Theoretical advantages of the 308-nm excimer laser and clinical data on the treatment of psoriasis and vitiligo will be discussed.

### Theoretical advantages of the 308-nm excimer laser

The excimer laser emits a wavelength of 308 nm produced using xenon and chlorine gases. Transmission of the beam of light is achieved by using an articulated arm. Spot size is variable from 14 to 30 mm in diameter depending on the model used. These technical characteristics provide this laser with many advantages over conventional phototherapies. High fluencies ( $>2 \text{ J/cm}^2$ ) are possible, which can be useful in thick plaques of psoriasis but not in vitiligo where only low fluencies are used. It is also possible to selectively turn the beam of light and thus to treat the specific area involved, sparing healthy skin. In vitiligo, this selectivity limits the unsightly tanning of perilesional skin, which is commonly observed with the other phototherapies. The articulated arm also makes it easier to reach areas that are usually difficult to treat, such as folds and mucosa. Disadvantages include the fact that the limited size of spots means that large surfaces ( $>20\%$  of total surface body area) cannot be treated and that purchase and maintenance costs of these devices remain quite expensive. The latter point has to be kept in mind when evaluating this laser alongside other treatment options.

The use of a monochromatic wavelength of 308 nm gives photobiological effects theoretically superior to those provided by NB-UVB. One of the main targets for UV-B is DNA contained in epidermal cells (keratinocytes, melanocytes) and, to a lesser extent, in dermal cells (fibroblasts). Inflammatory reactions could also be involved. The decrease in T-lymphocyte proliferation caused by inducing cellular apoptosis resulting from DNA lesions is likely to be one of the most important mechanisms of action of UV-B phototherapy. It has been demonstrated that 308 nm is the most efficient wavelength for inducing DNA lesions on lymphocytes.<sup>3</sup> The dose needed to induce apoptosis in 50% of T lymphocytes is  $95 \text{ mJ/cm}^2$  with the 308-nm excimer laser vs  $320 \text{ mJ/cm}^2$  with NB-UVB.<sup>4</sup> Similar levels of depletion of T lymphocytes due to apoptosis after treatment with 308-nm monochromatic excimer laser have been reported in psoriasis lesions.<sup>5</sup> The mechanism of action in vitiligo is more complicated. Stimulation of melanocyte migration and proliferation from progenitor niches located in hair

follicles is certainly the major factor. This stimulation is due to the direct action of UV on melanocytes but also to the action of cytokines secreted by keratinocytes. Recent data on the autoimmune origins of vitiligo underline the probable implications of the immunosuppressive action of UV in treating vitiligo.<sup>6</sup>

Finally, the 308-nm excimer laser differs from lamps used for conventional phototherapy in that it emits photons in an intense and a discontinued way (pulse width, 60 nanoseconds; distal pulse energy,  $4.6 \text{ mJ/cm}^2$ ). To date, the specific photobiological effects (immunomodulatory effect, action on presenting cells, pigmentation, and carcinogenic effects) of delivering photons in this way are unknown and can only be extrapolated from experimental studies and knowledge of NB-UVB phototherapy.

### Treatment of psoriasis using the 308-nm excimer laser

Psoriasis is a common chronic dermatologic disorder. Severe forms are very disabling and need systemic treatments. Localized forms of psoriasis, however, can be difficult to treat or recur frequently leading to decreased quality of life and psychological distress.<sup>7</sup> Many treatments are available for psoriasis, but the need for a well-tolerated therapy that can induce long-term remission remains obvious. Thus, it was logical for psoriasis to be the first dermatosis treated with the 308-nm excimer laser and also the first indication approved by the US Food and Drug Administration.

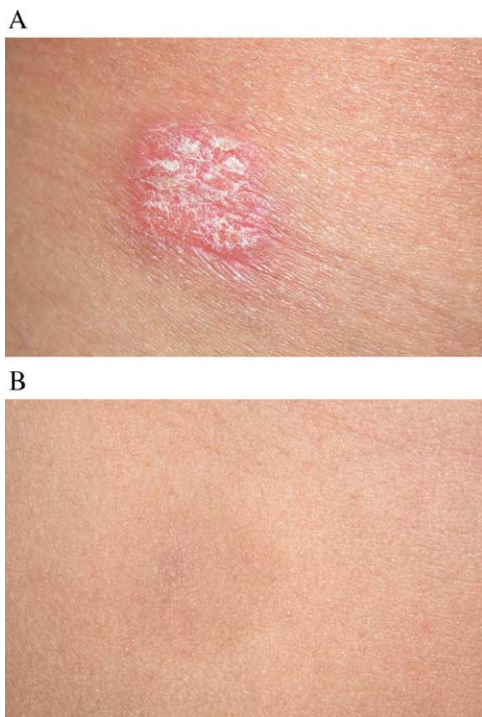
### Treatment of psoriasis vulgaris

Since 1997, several studies have evaluated the 308-nm excimer laser in the treatment of psoriasis vulgaris (Table 1).<sup>2,8-15</sup> The first series showed that this laser improved psoriasis lesions more rapidly than NB-UVB.<sup>2</sup> Next, taking advantage of the selectivity of the treatment, high fluencies (8-16 minimal erythema dose [MED]) were used. This therapeutic pattern provided very good results in efficacy and number of sessions required (an average of one to six sessions to obtain a clearance of lesions).<sup>8,9</sup> The immediate side effects were often severe, with burns and blister lesions leading to significant pain, and the possibility of long-term side effects (including skin cancers) of such high doses has led to the use of lower fluencies. Later studies used 1 to 3 MED with progressive increase in doses depending on clinical results and tolerance.<sup>10,11,13</sup> Sessions were performed two or three times a week. Results were very good, with an improvement of more than 90% in an average of 10 sessions. Interestingly, side effects with such fluencies were limited to hyperpigmentation, erythema, and, rarely, blisters. The selectivity of the laser allows doses to be adapted to each lesion rather than calculated from the MED as it is the case for conventional phototherapy.

**Table 1** Treatment of psoriasis vulgaris by the 308-nm excimer laser

Authors	No. of patients	No. of patients at the end of study	No. of treated plaques at the end of study	No. of sessions (per wk)	Fluencies (mJ/cm <sup>2</sup> )	Total no. of session	Mean cumulated doses (J/cm <sup>2</sup> )	Results	Side effects	Follow-up
Bonis et al <sup>2</sup>	10 (6 compared with NB-UVB)	10	NA	3	0.5 MED then increase of 61 per session	Mean, 8	4.8	Complete clearance (best to NB-UVB on cumulated dose and no. of sessions)	Erythema, transient hyperpigmentation	NA
Asawanonda et al <sup>8</sup>	13	13	52 (4 per patient)	2	0.5, 1 (low doses); 2, 3, 4 (medium doses); 8, 16 (high doses) MED	1, 2, 4, 20	NA	Best results with high fluencies	Erythema, blisters, pain (increasing with fluencies used)	Recurrence after 4 months for all plaques but those received high doses
Trehan and Taylor <sup>9</sup>	18	16	32 (2 per patient)	1 unique session	8 and 16 MED	1	NA	Improvement of >75% for 11/16 patients	Erythema, blisters, moderate pain	Persistence of an improvement after 4 months for 5 patients; recurrence for all the patients after 6 months
Feldman et al <sup>10</sup>	124	80	NA	2	3 MED then adapted from clinical response	10	NA	Improvement of >90% for 50% of patients	Erythema, hyperpigmentation, blisters	NA
Trehan and Taylor <sup>11</sup>	20	15	90	3	1 MED then increase of 25% to 30% at each session	Mean, 11	6.1	Improvement of >95%	Erythema, hyperpigmentation, rare blisters	3.5 months
Taneja et al <sup>12</sup>	18	14	44	2	Fixed doses depending on thickness of plaques then decrease depending on clinical improvement	Mean 10	8.8	Complete cleaning	Erythema	NA
Gerber et al <sup>13</sup>	120	102	NA	2 for 3 weeks then	3 MED then increase of 1 MED per session	Mean, 11	11.25	Improvement of >90% for 85% of patients	Erythema, blisters, hyperpigmentation	NA
	43	40	NA	1	MED calculated for each plaque then adapted depending on clinical response	Mean, 7	6.25	Improvement of >90% for 84% of patients	Erythema, blisters, hyperpigmentation	NA
Pahlajani et al <sup>14</sup>	7 (children)	4 (children)	4	2	3 MED (2 MED in fold) then reduction to 1 MED when plaque flattened	Mean, 10	NA	Mean improvement of 91%	Hyperpigmentation, blisters, erosions, pain, koebnerization	NA
	18 (adults)	12 (adults)	12	2		Mean, 12		Mean improvement of 62%		
Kollner et al <sup>15</sup>	15	15	15 (308-nm laser), 15 (308-nm lamp), 15 (NB-UVB)	3, 3, 3	1 MED then increase every 2 sessions	Mean: 24, 24, 24	53, 47, 65	Clearance: >90%, >90%, >90%	Erythema, pigmentation, blisters (laser, 40%; vs others, 27%)	Slight recurrence at 4 months (not statistically different for the three regimen)

NA indicates not available.



**Fig. 1** A, Abdominal plaque of psoriasis. B, One month after eight sessions of 308-nm excimer laser. Note the hyperpigmentation.

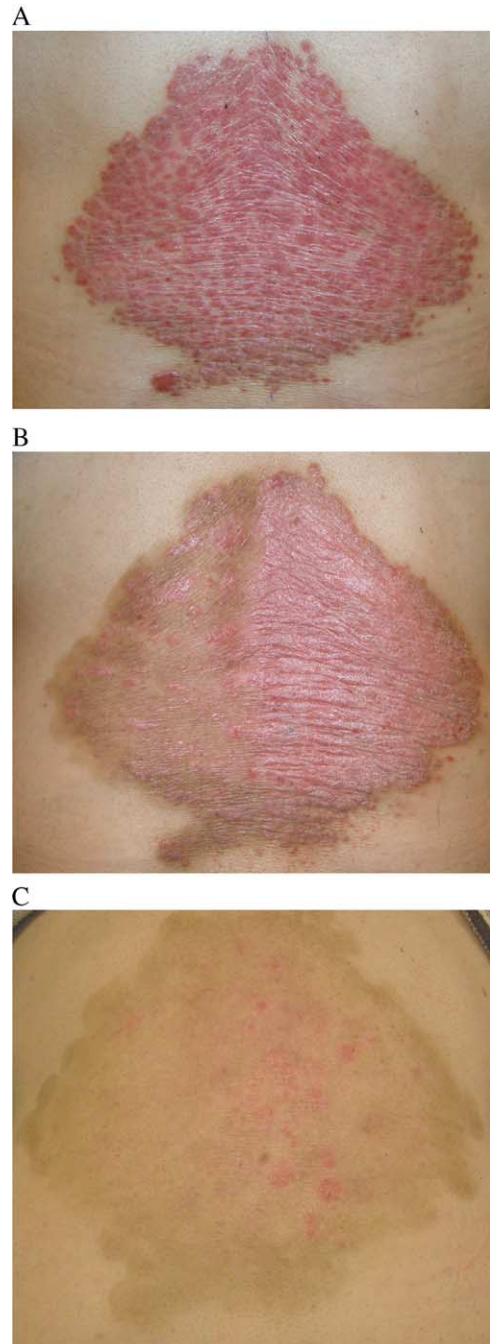
Determination of the MED for each plaque<sup>13</sup> or of fixed doses calculated from the thickness of the lesions, which are then decreased depending on the clinical improvement,<sup>12</sup> have been also proposed. These approaches could allow the cumulative dose and the total number of session necessary for obtaining a clinical healing to be decreased. Calculation of the MED for an erythematous psoriasis plaque is not so easy, however, and the use of the thickness of the lesion seems to be more reproducible (Figs. 1 and 2).

Data concerning the treatment of psoriasis with the 308-nm excimer laser in children are limited. One pilot study has shown efficacy and good tolerance of this technique in children.<sup>14</sup> By preventing unnecessary irradiation of healthy skin, the 308-nm excimer laser appears to be a good alternative treatment of pediatric forms of psoriasis, and a rapid growth in the use of this technique can be expected in the next few years.

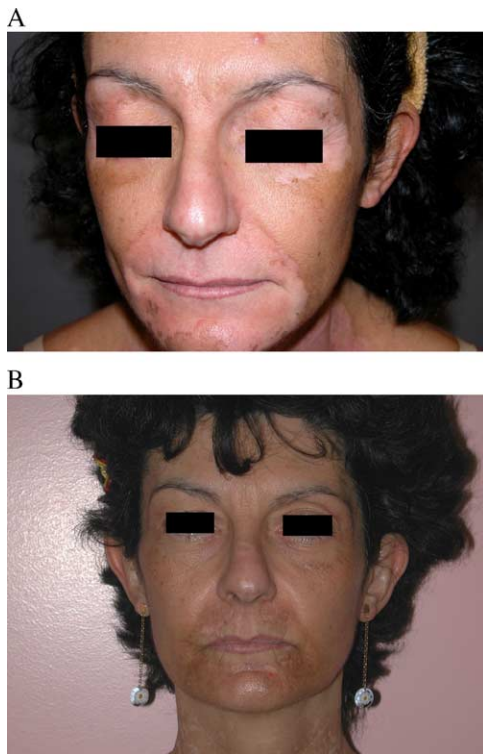The potential interest in such a laser, particularly in comparison to topical treatments, is the induction of remission with days free of treatment. Only a few series have reported follow-up studies. About 4 months without recurrences is commonly mentioned. A maintenance protocol with progressive decreases in the rate of sessions after initial clearance seems to maintain the level of clearance<sup>16</sup>; however, only five patients were included in this study and further investigations are still needed.

To the best of our knowledge, only two studies have compared the 308-nm excimer laser with other treatment

options. The results were contradictory because the 308-nm excimer laser appears to be clearly more effective than NB-UVB in the first study,<sup>2</sup> whereas results were similar to NB-UVB and 308-nm lamp in the second one.<sup>15</sup> The low numbers of patients and the differences in cumulative dose at the end of treatment in both series do not allow definitive conclusions to be drawn. The use of 308-nm excimer lamps appears very interesting. Like the



**Fig. 2** A, Recalcitrant lumbar plaque of psoriasis. B, Left side after five sessions of 308-nm excimer laser; right side untreated. C, Left side after 15 sessions; right side after 10 sessions.



**Fig. 3** A, Vitiligo of the face. B, One month after 24 sessions of 308-nm excimer laser.

308-nm excimer laser, they emit a wavelength of 308 nm and can selectively treat lesions, but the beam of light is not coherent and emission of photons is continuous. Interestingly, they cost much less than lasers and could allow a better diffusion of this technique. Data concerning the use of 308-nm excimer lamps for treating psoriasis or other chronic dermatologic disorders (such as vitiligo) are still very limited, and comparisons with the 308-nm excimer lasers are clearly needed. A meta-analysis comparing the 308-nm excimer laser with other treatment options has also reported the level of interest in this new technique.<sup>17</sup> Interpretation of the analysis remains very difficult because most of the treatments being compared are not designed for the same population of patients. Unlike conventional phototherapy (such as psoralen–UV-A and NB-UVB), the 308-nm excimer laser, because of its limited spot size, is dedicated to localized forms of psoriasis. Hence, the 308-nm excimer laser and other phototherapies appear to complement each other.

Further studies are needed better to compare this treatment with topical options such as topical steroids or calcipotriol. At first glance, these topical treatments appear to be less costly than the laser option; however, high rates of rapid recurrences, few days free of treatment, potential side effects (such as irritation, telangiectasia, skin atrophy, and others), and the necessity of applying cream or ointment daily have to be taken in consideration. In fact, a medical and economical study has reported that the 308-nm excimer

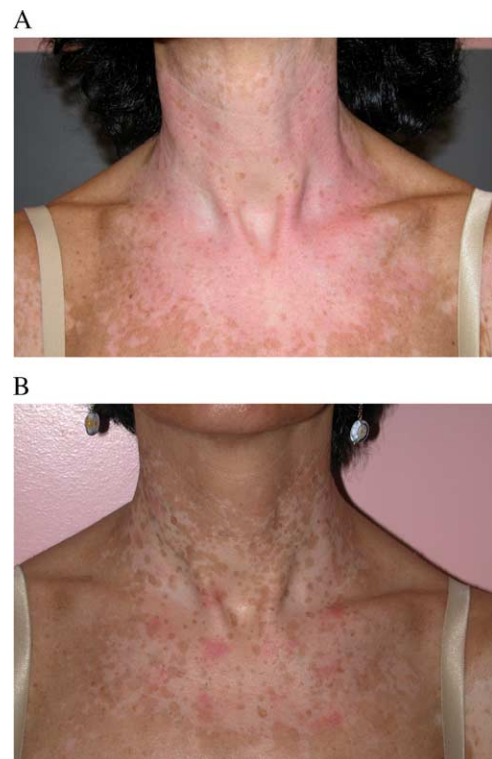laser provides additional and substantial clinical benefits for the second line of treatment of psoriasis without incremental cost to payers.<sup>18</sup>

### Treatment of other clinical form of psoriasis

The treatment of other forms of psoriasis with the 308-nm excimer laser has only been reported in pilot studies or case reports. The treatment of inverse psoriasis is always difficult. Folds are usually difficult to reach by conventional phototherapy, and side effects such as infection or irritation are not uncommon with topical treatments. A case of inverse psoriasis has been successfully treated with a 308-nm excimer laser.<sup>19</sup> We have successfully treated a severe form of genital psoriasis with a clinical healing after 16 sessions.<sup>20</sup> Recurrence occurred 3 months after the end of treatment.

Some authors have proposed combining the use of a 308-nm excimer laser with acitretin (instead of localized psoralen–UV-A) for the treatment of palmoplantar psoriasis.<sup>21</sup>

Finally, the efficacy of this laser has also been reported in severe forms of scalp psoriasis. Thirteen patients with scalp psoriasis unresponsive to topical steroids have been successfully treated over 15 sessions with the 308-nm excimer laser combined with an air blower device.<sup>22</sup> Another case of scalp psoriasis resistant to various topical



**Fig. 4** A, Vitiligo of the neck and trunk in the same woman as in Fig. 3. B, One month after 24 sessions of 308-nm excimer laser. Note the lower rate of repigmentation as compared with the face.

treatments was cleared after 23 sessions (twice weekly).<sup>23</sup> Interestingly, no recurrence was reported 10 weeks after the end of treatment.

### Treatment of vitiligo with the 308-nm excimer laser

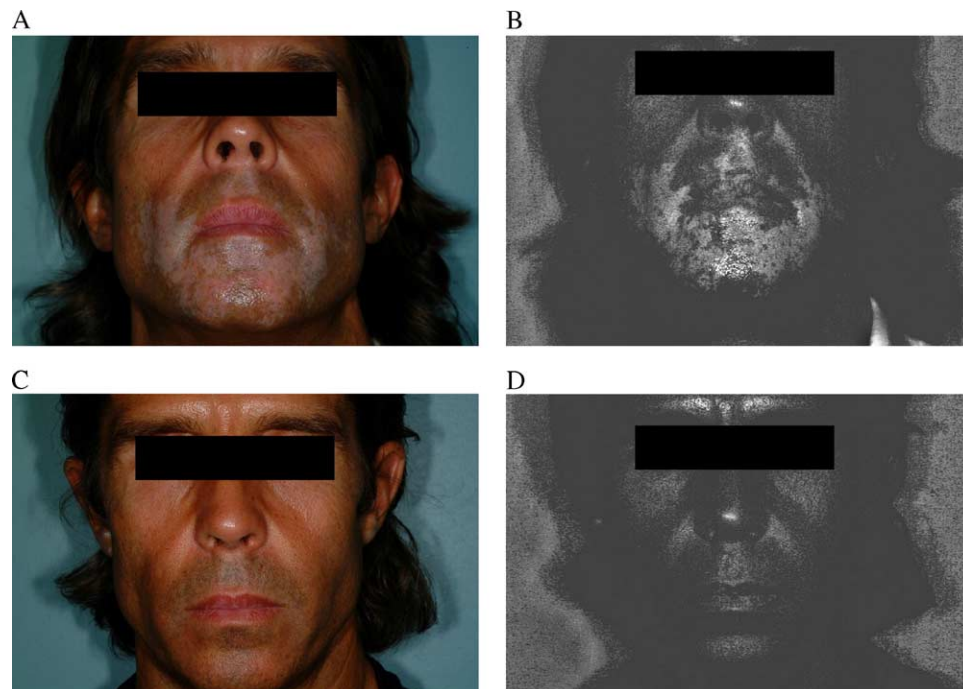Vitiligo is characterized by an acquired loss of melanocytes leading to depigmented plaques on skin and/or hair. Often wrongly considered to be a benign disorder, vitiligo can have an important psychological impact and lead to a significant decrease in the quality of life of affected individuals.<sup>24,25</sup> First-line treatment is medical and consists of topical steroids and phototherapy for localized and generalized vitiligo, respectively.<sup>26-29</sup> Surgery is possible for localized and stable vitiligo.<sup>30</sup> To date, however, no treatment provides constant satisfactory results. Thanks to its selectivity and propigmentary properties, the 308-nm excimer laser represents an interesting new approach for treating vitiligo (Figs. 3-7).

#### Monotherapy

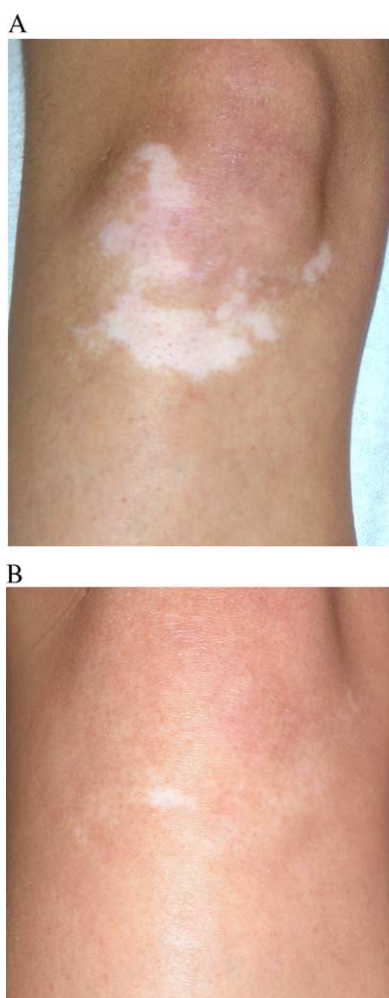
The use of the 308-nm excimer laser in treating vitiligo was first reported by Baltas et al.<sup>31</sup> Since then, many studies have shown the efficacy of this laser for repigmenting vitiligo plaques (Table 2).<sup>32-39</sup> Low fluencies (from 50 to 200 mJ/cm<sup>2</sup>) were used in one to three sessions a week for 1 to 6 months, depending on the study.

The number of plaques with repigmentation at the end of the treatment was excellent (57%-100%); although it is not only the number of plaques with repigmentation that is of interest, the result is only considered to be aesthetically satisfactory plaques reaching more than 75% repigmentation. On average, 20% to 30% of treated plaques reach these levels, but some series report conflicting results (from 0% to 75%). Among factors that can influence the clinical response to treatment, localization of the lesions seems to play a crucial role. In their study, Taneja et al.<sup>34</sup> report repigmentation of at least 75% in all the lesions located on the face vs none on the hands and feet. In our series, there was a statistically significant difference between results obtained on "UV-resistant" areas (extremities and bony prominences) and other ("UV sensitive") areas in which repigmentation rates were much higher.<sup>36</sup> The variability of some results reported certainly depends on the localization of target lesions.

Sessions can be performed once, twice, or three times a week. The repigmentation rate seems to be linked to the total number of sessions and not to their frequency.<sup>40</sup> It is difficult to know if the repigmentation is stable with time because the follow-up of existing series is short or nonexistent. A recent study reports no depigmentation 1 year after the end of sessions.<sup>35</sup> In our experience, about 15% of new depigmentation is observed 1 to 3 years after the end of treatment. Finally, tolerance is usually very good, and immediate side effects are limited to erythema and rare blister lesions.



**Fig. 5** A, Vitiligo of the face. B, Vitiligo of the face in UV light photography. C, One month after 6 weeks (12 sessions) of treatment with 308-nm excimer laser and twice daily application of 0.1% tacrolimus ointment. D, Ultraviolet light photography 1 month after the end of treatment.



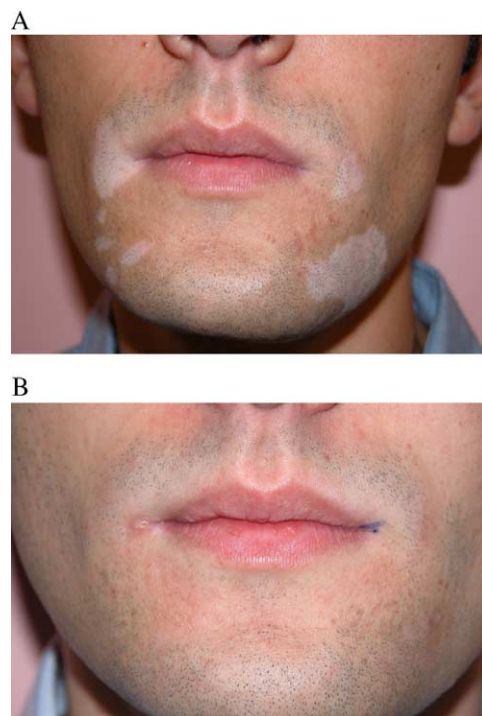
**Fig. 6** A, Vitiligo of the knee. B, One month after 12 weeks (24 sessions) of treatment with 308-nm excimer laser and twice daily application of 0.1% tacrolimus ointment.

### Combined treatment

Topical applications of 0.1% tacrolimus ointment have provided interesting results in the treatment of vitiligo lesions<sup>41</sup>; however, best results were obtained when concomitant sun exposure was achieved. Thus, two pilot prospective studies have evaluated use of the 308-nm excimer laser and tacrolimus ointment for synergy of effects. These studies have compared the efficacy of the excimer laser combined with 0.1% tacrolimus ointment with excimer laser monotherapy<sup>42</sup> or laser associated with a placebo.<sup>43</sup> In the first series, two sessions per week were performed vs three in the second. In both cases, a total of 24 sessions were carried out and 0.1% tacrolimus ointment was applied twice a day. Results were comparable and clearly showed a greater efficacy and shorter response to treatment with combined therapy as compared with excimer laser alone. Tolerance was good and immediate side effects were limited to constant erythema and rare bullous or itching lesions. Although these results are very encouraging, it is still necessary to confirm

them in a larger population. The increased risk for cutaneous cancers observed in organ transplant patients treated with systemic tacrolimus has led to the restriction of UV exposure during local treatment with topical tacrolimus, although it must be emphasized that the barrier function of vitiligo skin is normal. This results in poor penetration of tacrolimus ointment within the interfollicular epidermis. Furthermore, studies in mouse skin have shown that tacrolimus applications can protect against UV-induced damage on DNA.<sup>44</sup> Long-term follow-up, however, is still lacking and the risk of inducing carcinogenic mutations cannot be excluded. For these reasons, such a combination should, for the moment, be limited to controlled studies.

No study has yet evaluated the combination of the 308-nm excimer laser and topical steroids. Combination of UV-A with a topical steroid has been shown to be more efficient than UV-A or topical steroid used alone to repigment vitiligo plaques.<sup>45</sup> An approach using synergistic treatments appears to be necessary to obtain optimal percentages of repigmentation in vitiligo. In our experience, combination of the 308-nm excimer laser and one daily application of topical steroid (class II in most cases) appears to be superior to laser alone and seems to give results approaching those obtained by combining the 308-nm excimer laser with tacrolimus (T Passeron and J-P Ortonne, unpublished data, 2005). If these results are confirmed, such a combination, which carries fewer implications for long-term carcinogenic risks, could be very useful.



**Fig. 7** A, Vitiligo of the face. B, One month after 12 weeks (24 sessions) of treatment with 308-nm excimer laser and one daily application of 0.1% desonide cream.

**Table 2** Treatment of vitiligo by the 308-nm excimer laser

Authors	No. of patients	No. of patients at the end of study	No. of treated plaques at the end of study	No. of sessions by week	Length of treatment (wk)	Plaques with some repigmentation (%)	Plaques with repigmentation of >75% (%)	Side effects	Follow-up
Spencer et al <sup>32</sup>	18	6	11	3	4	82	18	Erythema	NA
Baltas et al <sup>33</sup>	6	4	4	2	24	100	75	Erythema, pruritus	No depigmentation after 3 months
Taneja et al <sup>34</sup>	18	15	18	2	16	100	33	Erythema	NA
Esposito et al <sup>35</sup>	24	24	NA	2	36	79	29	Erythema, pruritus	No depigmentation after 12 months
Ostovari et al <sup>36</sup>	35	31	52	2	12	88	27	Erythema, five bullous lesions	No depigmentation after 1 month
Kawalek et al <sup>43</sup>	8	6	10 Excimer + placebo	3	8	100	20 Excimer + placebo	Erythema, one bullous lesion	NA
			10 Excimer + tacrolimus			100	50 Excimer + tacrolimus	Some stinging and burning sensations with tacrolimus	
Passeron et al <sup>42</sup>	14	14	20 Excimer alone	2	12	85	20 Excimer alone	Erythema, four bullous lesions (two and two)	No depigmentation after 1 month
			23 Excimer + tacrolimus			100	70 Excimer + tacrolimus	Stinging with tacrolimus (five cases)	
Choi et al <sup>37</sup>	69	50	108	2	15	72	15,7 (33 on face and neck, 0 on extremities and bony prominences)	Erythema (11%), bullous lesions (11%)	NA
Hadi et al <sup>38</sup>	32	55	55	2	15	100	53 (71 on face, 0 on hands and feet)	NA	NA
Hong et al <sup>39</sup>	8	8	23 Excimer, 23 NB-UVB	2	10	57, 53	0 (17 with repigmentation of >50%), 0 (0 with repigmentation of >50%)	NA	NA



## Conclusions

The 308-nm excimer laser certainly appears to be a useful treatment of dermatologic disorders, especially for psoriasis and vitiligo. Its selectivity is one of its main advantages but also limits its use to lesions spread across less than 20% of the body surface area; thus, it should not be matched against conventional phototherapy but be considered as a complementary treatment option. Several prospective studies have shown its efficacy and good tolerance in psoriasis vulgaris and vitiligo; however, long-term follow-up is still lacking and optimal parameters for treatment have not been fully determined, especially for psoriasis. The need for maintenance sessions is also still in question. Indeed, further prospective studies are still necessary, including assessing the efficacy and safety of combination therapies in vitiligo and investigating the use of this laser in other forms of psoriasis.

## References

- Parrish JA. Phototherapy and photochemotherapy of skin diseases. *J Invest Dermatol* 1981;77:167-71.
- Bonis B, Kemeny L, Dobozy A, et al. 308 nm UVB excimer laser for psoriasis. *Lancet* 1997;350:1522.
- de With A, Greulich KO. Wavelength dependence of laser-induced DNA damage in lymphocytes observed by single-cell gel electrophoresis. *J Photochem Photobiol B* 1995;30:71-6.
- Novak Z, Bonis B, Baltas E, et al. Xenon chloride ultraviolet B laser is more effective in treating psoriasis and in inducing T cell apoptosis than narrow-band ultraviolet B. *J Photochem Photobiol B* 2002;67:32-8.
- Bianchi B, Campolmi P, Mavilia L, et al. Monochromatic excimer light (308 nm): an immunohistochemical study of cutaneous T cells and apoptosis-related molecules in psoriasis. *J Eur Acad Dermatol Venereol* 2003;17:408-13.
- Ongenae K, Van Geel N, Naeyaert JM. Evidence for an autoimmune pathogenesis of vitiligo. *Pigment Cell Res* 2003;16:90-100.
- Shampogna F, Sera F, Abeni D. Measures of clinical severity, quality of life, and psychological distress in patients with psoriasis: a cluster analysis. *J Invest Dermatol* 2004;122:602-7.
- Asawanonda P, Anderson RR, Chang Y, Taylor CR. 308-nm excimer laser for the treatment of psoriasis: a dose-response study. *Arch Dermatol* 2000;136:619-24.
- Trehan M, Taylor CR. High-dose 308-nm excimer laser for the treatment of psoriasis. *J Am Acad Dermatol* 2002;46:732-7.
- Feldman SR, Mellen BG, Housman TS, et al. Efficacy of the 308-nm excimer laser for treatment of psoriasis: results of a multicenter study. *J Am Acad Dermatol* 2002;46:900-6.
- Trehan M, Taylor CR. Medium-dose 308-nm excimer laser for the treatment of psoriasis. *J Am Acad Dermatol* 2002;47:701-8.
- Taneja A, Trehan M, Taylor CR. 308-nm excimer laser for the treatment of psoriasis: induration-based dosimetry. *Arch Dermatol* 2003;139:759-64.
- Gerber W, Arheilger B, Ha TA, Hermann J, Ockenfels HM. Ultraviolet B 308-nm excimer laser treatment of psoriasis: a new phototherapeutic approach. *Br J Dermatol* 2003;149:1250-8.
- Pahlajani N, Katz BJ, Lozano AM, Murphy F, Gottlieb A. Comparison of the efficacy and safety of the 308 nm excimer laser for the treatment of localized psoriasis in adults and in children: a pilot study. *Pediatr Dermatol* 2005;22:161-5.
- Kollner K, Wimmershoff MB, Hintz C, Landthaler M, Hohenleutner U. Comparison of the 308-nm excimer laser and a 308-nm excimer lamp with 311-nm narrowband ultraviolet B in the treatment of psoriasis. *Br J Dermatol* 2005;152:750-4.
- Housman TS, Pearce DJ, Feldman SR. A maintenance protocol for psoriasis plaques cleared by the 308 nm excimer laser. *J Derm Treat* 2004;15:94-7.
- Rodewald EJ, Housman TS, Mellen BG, Feldman SR. The efficacy of 308 nm laser treatment of psoriasis compared to historical controls. *Dermatol Online J* 2001;7:4.
- Marchetti A, Feldman SR, Kimball AB, et al. Treatments for mild-to-moderate recalcitrant plaque psoriasis: expected clinical and economic outcomes for first-line and second-line care. *Dermatol Online J* 2005;11:1.
- Mafong EA, Friedman PM, Kauvar AN, et al. Treatment of inverse psoriasis with the 308 nm excimer laser. *Dermatol Surg* 2002;28:530-2.
- Ostovari N, Passeron T, Zakaria W, et al. Traitement du psoriasis génital par le laser excimer à 308 nm. *Journ Derm de Paris* 2003;209.
- Spuls PI, Hadi S, Rivera L, Lebwohl M. Retrospective analysis of the treatment of psoriasis of the palms and soles. *J Derm Treat* 2003;14(Suppl 2):21-5.
- Taylor CR, Racette AL. A 308-nm excimer laser for the treatment of scalp psoriasis. *Lasers Surg Med* 2004;34:136-40.
- Gupta SN, Taylor CR. 308-nm excimer laser for the treatment of scalp psoriasis. *Arch Dermatol* 2004;140:518-20.
- Kent G, Al'Abadie M. Psychologic effects of vitiligo: a critical incident analysis. *J Am Acad Dermatol* 1996;35:895-8.
- Parsad D, Pandhi R, Dogra S, Kanwar AJ, Kumar B. Dermatology Life Quality Index score in vitiligo and its impact on the treatment outcome. *Br J Dermatol* 2003;148:373-4.
- Njoo MD, Spuls PI, Bos JD, Westerhof W, Bossuyt PM. Nonsurgical repigmentation therapies in vitiligo. Meta-analysis of the literature. *Arch Dermatol* 1998;134:1532-40.
- Mofty ME, Zaher H, Esmat S, et al. PUVA and PUVB in vitiligo—are they equally effective? *Photodermatol Photoimmunol Photomed* 2001;17:159-63.
- Scherschun L, Kim JJ, Lim HW. Narrow-band ultraviolet B is a useful and well-tolerated treatment for vitiligo. *J Am Acad Dermatol* 2001;44:999-1003.
- Taneja A. Treatment of vitiligo. *J Derm Treat* 2002;13:19-25.
- van Geel N, Ongenae K, Naeyaert JM. Surgical techniques for vitiligo: a review. *Dermatology* 2001;202:162-6.
- Baltas E, Nagy P, Bonis B, et al. Repigmentation of localized vitiligo with the xenon chloride laser. *Br J Dermatol* 2001;144:1266-7.
- Spencer JM, Nossa R, Ajmeri J. Treatment of vitiligo with the 308-nm excimer laser: a pilot study. *J Am Acad Dermatol* 2002;46:727-31.
- Baltas E, Csoma Z, Ignacz F, Dobozy A, Kemeny L. Treatment of vitiligo with the 308-nm xenon chloride excimer laser. *Arch Dermatol* 2002;138:1619-20.
- Taneja A, Trehan M, Taylor CR. 308-nm excimer laser for the treatment of localized vitiligo. *Int J Dermatol* 2003;42:658-62.
- Esposito M, Soda R, Costanzo A, Chimenti S. Treatment of vitiligo with the 308 nm excimer laser. *Clin Exp Dermatol* 2004;29:133-7.
- Ostovari N, Passeron T, Zakaria W, et al. Treatment of vitiligo by 308-nm excimer laser: an evaluation of variables affecting treatment response. *Lasers Surg Med* 2004;35:152-6.
- Choi KH, Park JH, Ro YS. Treatment of vitiligo with 308-nm xenon-chloride excimer laser: therapeutic efficacy of different initial doses according to treatment areas. *J Dermatol* 2004;31:284-92.
- Hadi SM, Spencer JM, Lebwohl M. The use of the 308-nm excimer laser for the treatment of vitiligo. *Dermatol Surg* 2004;30:983-6.
- Hong SB, Park HH, Lee MH. Short-term effects of 308-nm xenon-chloride excimer laser and narrow-band ultraviolet B in the treatment of vitiligo: a comparative study. *J Korean Med Sci* 2005;20:273-8.
- Hofer A, Hassan AS, Legat FJ, Kerl H, Wolf P. Optimal weekly frequency of 308-nm excimer laser treatment in vitiligo patients. *Br J Dermatol* 2005;152:981-5.

41. Lepe V, Moncada B, Castaneda-Cazares JP, et al. A double-blind randomized trial of 0.1% tacrolimus vs 0.05% clobetasol for the treatment of childhood vitiligo. *Arch Dermatol* 2003;139:581-5.
42. Passeron T, Ostovari N, Zakaria W, et al. Topical tacrolimus and the 308-nm excimer laser: a synergistic combination for the treatment of vitiligo. *Arch Dermatol* 2004;140:1065-9.
43. Kawalek AZ, Spencer JM, Phelps RG. Combined excimer laser and topical tacrolimus for the treatment of vitiligo: a pilot study. *Dermatol Surg* 2004;30:130-5.
44. Tran C, Lubbe J, Sorg O, et al. Topical calcineurin inhibitors decrease the production of UVB-induced thymine dimers from hairless mouse epidermis. *Dermatol* 2005;211:341-7.
45. Westerhof W, Nieuweboer-Krobotova L, Mulder PG, Glazenburg EJ. Left-right comparison study of the combination of fluticasone propionate and UV-A vs. either fluticasone propionate or UV-A alone for the long-term treatment of vitiligo. *Arch Dermatol* 1999; 135:1061-6.